



PATIENT

Reggie Bennet

SPECIES

Canine

BREED

English Bulldog

SEX

MN

AGE

7y

WEIGHT

64lbs

INTERPRETED BY

Maggie Machen
Lamy, DVM, DACVIM
(Cardiology)

IMAGING PERFORMED BY

Tom McNeill, DVM

HOSPITAL NAME

Fitchburg VH

REFERRING VET

Dr. Babich

INVOICE

27605

DATE

11/22/22

PRESENTING CLINICAL SIGNS

History: No symptoms, but previous echo revealed suspect chemodectoma/heart based mass found. Patient is on a grain-free diet. Pertinent previous echo findings (MOVES 5/2022): ST opacity near aortic root; 0.9x1.1cm, remainder NSF without DCM (no measurements included)

ECHOCARDIOGRAM FINDINGS

2D, m-mode, color flow and doppler imaging is available. Heterogenous echogenicity mass associated with the heart base, 1.9x2.7cm in largest cross section. The mass is well encapsulated and near the base of the aortic root (see below). No obvious obstruction to blood flow or imposition on cardiac chambers at this time. No mitral regurgitation, normal mitral valve. No TR. Normal right heart chamber dimensions. LV function is adequate. Left atrium is normal in diameter. LV is normal in diameter. The pulmonic and aortic valves are normal in appearance. Normal LVOT and RVOT velocity. No AI or PI identified. No pericardial or pleural effusion.

CARDIAC CHART

CANINE CARDIAC PARAMETERS	MR VMAX (m/s)	TR VMAX (m/s)	LA/AO (Boon method)	LA/AO (Heart Base; Swe)	FS (%)	EF (%)	EPSS (cm)
NORMAL PARAMETER	4.5-5.5	<2.7	1.3	<1.6	28-40	40-100	<0.6
PATIENT	NA	NA	NM	1.3	382	59	0.59
CANINE CARDIAC PARAMETERS	HR (BPM)	AV VMAX (m/s)	PV MAX (m/s)	BODY WEIGHT (kg)	LA 2D short axis Base view (cm)	LVIDd Avg; 2D and m-mode short axis (cm)	LVIDs Avg; 2D and m-mode short axis (cm)
NORMAL PARAMETER	50-100	0.7-1.7	0.7-1.6	BELOW	BELOW	BELOW	BELOW
PATIENT	120	1.5	1.2		3.0	4.7	3.2
*Normal chamber parameters expressed as a mean value (SD)				3	1.27 (5.3)	2.46 (2.46)	1.36 (5.5)
BODY WEIGHT DEPENDENT PARAMETERS <i>*Note: All measurements based upon multi-modal images and methods. An average value is reported.</i>				5	1.40 (4.5)	2.74 (5.2)	1.60 (4.7)
				10	1.50 (3.8)	3.27 (3.5)	2.06 (3.1)
				15	1.83 (2.0)	3.71 (2.4)	2.43 (2.1)
				20	2.02 (1.9)	4.14 (2.2)	2.80 (2.0)
				25	2.18 (2.4)	4.48 (2.9)	3.10 (2.5)
				30	2.33 (3.3)	4.83 (3.9)	3.39 (3.4)
				35	2.48 (4.3)	5.17 (5.0)	3.69 (4.5)
				40	2.62 (5.2)	5.48 (6.1)	3.96 (5.4)
50	2.88 (7.1)	6.07 (8.3)	4.46 (7.4)				
Adapted from June Boon, Veterinary Echocardiography, 1998 Rishniw M and Hollis NE, J Vet Intern Med 2000; 14:429-435 Hansson et al, Vet Rad and Ultrasound 2002 Bonagura et al. Echocardiography: principles of interpretation, Vet Clin North Am 15:1177, 1995							

INTERPRETATION OF THE FINDINGS & FURTHER RECOMMENDATIONS

Findings are similar to the prior study, with normal cardiac structure and function. There is no significant LV dilation, and systolic function is adequate. The previously noted heart-based tumor persists similar to what is described previously. While potentially a mild increase in size is noted comparatively, the mass remains relatively small and is not imposing on blood flow at this time. No evidence of diet-related cardiomyopathy at this time.



PATIENT

Reggie Bennet

The most likely tumor type given this location and breed is a chemodectoma; however, other differentials cannot be ruled out. Chemodectomas are often incidental findings, only causing clinical signs if blood flow is obstructed, pericardial effusion occurs, or a metastatic lesion causing systemic issues. Given the breed and lack of pericardial effusion, it is difficult to definitively evaluate the remainder of the aortic body and a thoracic CT may be helpful to screen for other lesions. No additional issues are identified.

SPECIES

Canine

BREED

English Bulldog

The prognosis with cardiac chemodectomas is fair, with an MST of 1-2 years. The limiting factor is often hemorrhage into the pericardium. Other sequelae include impingement of cardiac blood flow secondary to tumor growth, or metastasis to the thorax or abdomen. Chemotherapy and/or radiation therapy can also be discussed with an Oncologist.

SEX

MN

Mild activity restriction and omega fatty acid supplementation are recommended in any arrhythmic patient.

AGE

7y

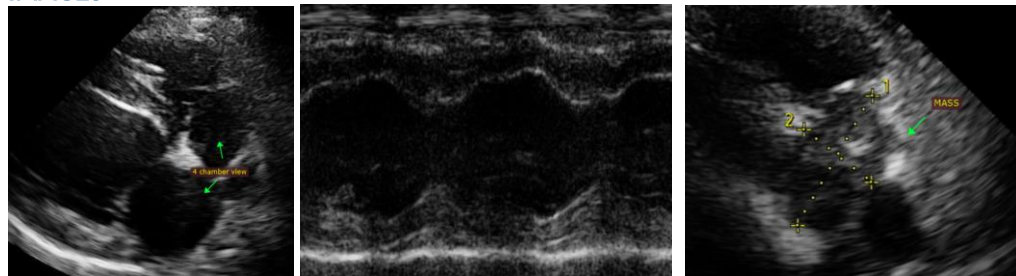
No cardiac medications are indicated at this time. Monitor for development of a cough, labored breathing, exercise intolerance or collapse episodes.

WEIGHT

64lbs

Recommend reassess tumor size in 6-12 months, sooner if clinical signs arise. Further evaluation of tumor extent is recommended through thoracic CT.

IMAGES



The information and recommendations provided are based on the images presented by the referring veterinarian. No evaluation can be communicated regarding pathology that was not visible in the image/video clips provided.

INTERPRETED BY

Maggie Machen Lamy, DVM, DACVIM (Cardiology)

Thank you for this referral. If the clinical or image interpretation does not parallel your findings or if I can be of any further assistance please contact me.

HOSPITAL NAME

Fitchburg VH

Maggie Machen Lamy, DVM
Diplomate of the American College of Veterinary Internal Medicine (Cardiology)
info@sonopath.com

REFERRING VET

Dr. Babich

INVOICE

27605

DATE

11/22/22